



## Use of Autologous Growth Factors in Lumbar Spinal Fusion

G. L. LOWERY, S. KULKARNI, and A. E. PENNISI

Research Institute International, Inc., Gainesville, FL, USA

The results of spinal fusion, especially posteriorly above the lumbosacral junction, have been mixed. Autologous growth factor concentrate (AGF) prepared by ultraconcentration of platelets contains multiple growth factors having a chemotactic and mitogenic effect on mesenchymal stem cells and osteoblasts and may play a role in initiating bone healing. The purpose of this retrospective study is to review our results with AGF in lumbar spinal fusions. To date, AGF has been used in 39 patients having lumbar spinal fusion. The study group consisted of the first 19 consecutive cases to allow at least 6 months follow-up. The average follow-up was 13 months (range 6 to 18 months). Follow-up compliance was 91%. There were 7 men and 12 women. Average age was 52 years (range 30–72 years). Nine patients had prior back surgery. There were 8 smokers. AGF was used in posterior ( $n = 15$ ) or anterior intradiscal ( $n = 4$ ) fusions. AGF was used with autograft and coralline hydroxyapatite in all posterior fusions, and autograft, coral, and intradiscal spacer (carbon fiber spinal fusion cages or Synthes femoral ring) in intradiscal fusions. Posterior stabilization was used in all cases. Eight cases were single-level fusions, 6 were two-level, and 1 was a three-level fusion. Autologous iliac crest bone graft was taken in 14 cases and local autograft used in 5 cases. Posteriorly, a total of 23 levels were fused; of these, nine were at L5–S1, eight at L4–L5, five at L3–L4, and one at L2–L3. No impending pseudoarthroses were noted on plain radiographic examination at last follow-up visit. Solid fusion was confirmed in 3 patients having routine hardware removal, and in 2 patients who had surgery at an adjacent level. There was one posterior wound infection, which was managed without sequelae. When used as an adjunct to autograft, AGF offers theoretical advantages that need to be examined in controlled studies. Further study is necessary to determine whether coralline hydroxyapatite used as a bone graft extender in lumbar spinal fusion may help to obviate the need for secondary site graft harvesting. (Bone 25: 47S–50S; 1999) © 1999 by Elsevier Science Inc. All rights reserved.

**Key Words:** Platelet; Autologous; Growth factors; Bone graft enhancer; Lumbar spine; Coralline hydroxyapatite.

Address for correspondence and reprints: Gary L. Lowery, M.D., Ph.D., Research Institute International Inc., 6400 W Newberry Road, Suite 206, Gainesville, FL 32605. E-mail: gll@glldmhd.com

### Introduction

The vital role played by local growth factors in the complex series of events that lead to bone healing and graft incorporation has been known for almost three decades. The discovery of bone morphogenetic protein (BMP) in 1965 by Marshall Urist has led to various studies for identification and isolation of purified forms of a variety of growth factors that play roles in osteogenesis. A large number of polypeptides have been identified since then and have been grouped based upon their structural homologies into at least 20 families and superfamilies.<sup>13</sup> The most widely studied of these are the insulin-like growth factor (IGF), epidermal growth factor (EGF), fibroblast growth factor (FGF), platelet-derived growth factor (PDGF), and the transforming growth factor (TGF) group, of which, the BMPs form a subgroup. The potentially beneficial effects of PDGF on bone formation *in vitro* has been described in many studies,<sup>2,3,5,6,9,15,17</sup> and *in vivo* stimulation of bone formation by TGF- $\beta$  has also been demonstrated in rats.<sup>8,14</sup> Various studies have demonstrated the chemotactic and mitogenic effects of local growth factors on mesenchymal cells as well as osteoblasts and periosteal fibroblasts.<sup>4,5,12,16</sup> Bone formation at the site of a fracture or at the site of grafting is initiated by a process of fibrin clot formation, platelet aggregation, and degranulation. Platelet granules contain a variety of physiologically active substances such as catecholamines, serotonin, calcium ions, ATP, albumin, fibrinogen, osteonectin, osteocalcin, various clotting factors, and the locally active growth factors like PDGF, TGF- $\beta$ , IGF-I, IGF-II, FGF, and EGF.<sup>17</sup> PDGF has been shown to be chemotactic to fibroblasts as well as to monocytes and primitive mesenchymal cells.<sup>3,16</sup> TGF- $\beta$  has also been reported to have chemotactic activity towards osteoblast precursors.<sup>10</sup> Both PDGF and TGF- $\beta$  have mitogenic activity by stimulation of DNA synthesis and cell replication.<sup>6</sup> Caplan<sup>4</sup> has described three sites in bone containing undifferentiated stem cells that are capable of differentiating into osteoblasts, namely, the marrow, periosteum, and perivascular sheath. PDGF and TGF- $\beta$  have a chemotactic and mitogenic effect on these cells that causes them to multiply and secrete additional growth factors. Then, under the influence of other cytokines and local environmental conditions such as pH, oxygen tension, and micromotion, these cells undergo a differentiation into osteoblasts or chondroblasts. Collagen and protein synthesis by osteoblasts is also stimulated by PDGF but also needs the presence of IGF-I.<sup>7</sup> PDGF probably enhances the secretion of IGF-I by the osteoblasts and mesenchymal stem cells, which then accelerates the formation of collagenous matrix.<sup>9</sup> PDGF also seems to enhance the activity of BMP in promoting cartilage and bone formation.<sup>8</sup> All the other factors present in the platelet granules also play roles in osteogenesis.<sup>11</sup> Kasperk et al. have noted that "since multiple growth factors are present in the bone cell microenvironment at a time,

interactions between the factors could be important for regulation of bone cell proliferation.<sup>14,9</sup> Their study of growth factor interactions has concluded that TGF- $\beta$ , IGF-II, and FGF modify the activity of other growth factors and cytokines and actually have a synergistic effect in combination.

We have used autologous platelet ultraconcentrate obtained by a proprietary centrifugation technique in posterolateral as well as interbody spinal fusions. To our knowledge, this is the first report of the use of platelet ultraconcentrate as a biological enhancer for spinal fusion.

### Materials and Methods

A retrospective review of patients who had lumbar spinal fusion using autologous growth factors (AGF) concentrate between August 1997 and August 1998 is reported. To date, AGF concentrate has been used in 39 lumbar fusions. The first 21 consecutive cases are at least 6 months postsurgery. Of these 21 patients, 1 died of multiple systemic complications within 2 months of surgery. One patient relocated. Six months of follow-up is available for 19 patients (91%). Average follow-up was 13 months (range 6 to 18 months).

There were 7 men and 12 women. Average age was 52 years (range 30 to 72 years). Nine patients had prior back surgery. There were 8 smokers (42%). Six patients (31%) were overweight (body mass index [BMI] > 27), 4 were worker's compensation cases, and 5 had positive significant medical history.

AGF was used in posterolateral fusion in 15 cases and in intradiscal fusion in 4 cases. Posterior instrumentation was used in all cases.

Posterolateral fusion and instrumentation with or without intradiscal fusion and laminectomy was performed in 15 cases. The indication for surgery in these cases were failed anterior fusion in 5, failed lumbar laminectomy syndrome in 3, spinal stenosis and radiculopathy in 5, iatrogenic flat back syndrome in 1, and transitional syndrome with solid previous fusion at an adjacent level in 1 case. Seven of these 15 patients had concomitant intradiscal fusion, 7 had only posterolateral fusion with instrumentation, and 1 patient with iatrogenic flat back had extension osteotomy with posterior fusion and instrumentation. Eight of these patients also had decompressive laminectomies. In this group, the 7 patients with concomitant intradiscal fusion had titanium surgical mesh (TSM) or femoral ring spacer with autograft. Posterolateral fusion was performed using a mixture of autograft and AGF concentrate activated by thrombin and coralline hydroxyapatite (HA; Interpore-Cross, Irvine, CA) in all 15 of these patients. A total of 23 levels posteriorly were fused (bilaterally). Of these, nine were at L5-S1, eight at L4-L5, five at L3-L4, and one at L2-L3. Single-level posterior fusion was performed in 8 cases, two-level in 6 cases, and three-level in one case. All patients had posterior instrumentation. Anterior intradiscal fusion with posterior instrumentation (no posterior fusion) was performed in 4 cases. Two of these had discogenic pain. 1 had spondylolisthesis with radiculopathy at L4-L5, and 1 had transitional syndrome. All 4 intradiscal cases without posterior fusion were performed using HA dowels with autograft and AGF concentrate placed in carbon fiber cages or TSM.

### Surgical Technique (Figure 1)

One unit of whole blood (450 cc) was drawn from the patients at the beginning of the surgery after obtaining a baseline platelet count. This was subjected to pheresis through a cell saver to obtain a buffy coat concentrate or platelet concentrate (Pcon) of about 60 mL volume while the platelet-poor plasma and red blood cells (RBCs) were collected and re-infused into the patient.

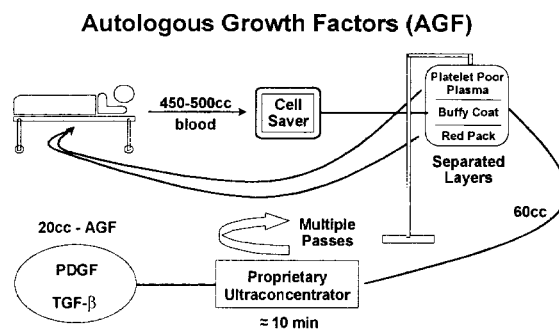


Figure 1. Operative setup of method used to obtain AGF concentrate.

A sample of the buffy coat concentrate was saved for counting the platelet levels, and then the buffy coat preparation was subjected to a proprietary ultraconcentration method to reduce the volume to about 20 cc. This ultraconcentrate or AGF concentrate was then tested for platelet count as well as for gel formation by mixing 1 cc of concentrate with 1 drop thrombin (100 U/cc). With improved concentration techniques, we have lately been obtaining about 180 cc of platelet concentrate from one unit of blood, which is further ultraconcentrated to about 60 cc of AGF concentrate.

With the surgeon ready to apply the graft, the desired graft was covered by a simultaneous application of the AGF concentrate and approximately 3-6 cc of thrombin to obtain a gel that was thoroughly mixed with the graft before applying it to the recipient site.

A preliminary study of the actual concentration of the TGF- $\beta$  and PDGF levels was also done in a few samples.

### Results

In our series, the average platelet count increased from  $234 \times 10^6$  cells/mL baseline to  $718 \times 10^6$  cells/mL in the platelet concentrate stage. This platelet concentrate was then further concentrated to get AGF concentrate that showed average platelet count values of  $1333 \times 10^6$  cells/mL, resulting in a 575% overall increase.

No major complications were seen in the study group. One patient needed a primary dural repair for an incidental durotomy, and 1 patient with percutaneously placed posterior instrumentation had screw misplacement that required repositioning. One elderly, overweight, diabetic, and hypertensive female patient had lumbar wound infection that was treated by inflow-outflow irrigation 2 weeks postoperatively, and with long-term parenteral antibiotics. She went on to show good posterolateral fusion bilaterally with no further sequelae.

Three patients with intradiscal fusion stabilized with suprafascially placed pedicular screw fixation underwent routine removal of instrumentation at about 6 months postoperatively, and a solid anterior fusion was confirmed at this time by stressing the pedicle screws without motion under fluoroscopy. Two of the circumferential fusion cases underwent intradiscal fusions for disc degeneration at adjacent levels; their posterolateral fusion was confirmed to be solid at the time of the second surgery. Thus, bony fusion was confirmed intraoperatively in 5 of 19 patients (26%). In the remaining 14 patients, radiographs taken at their last follow-up showed solid or maturing fusion in all cases with no radiological or clinical evidence of pseudoarthrosis.

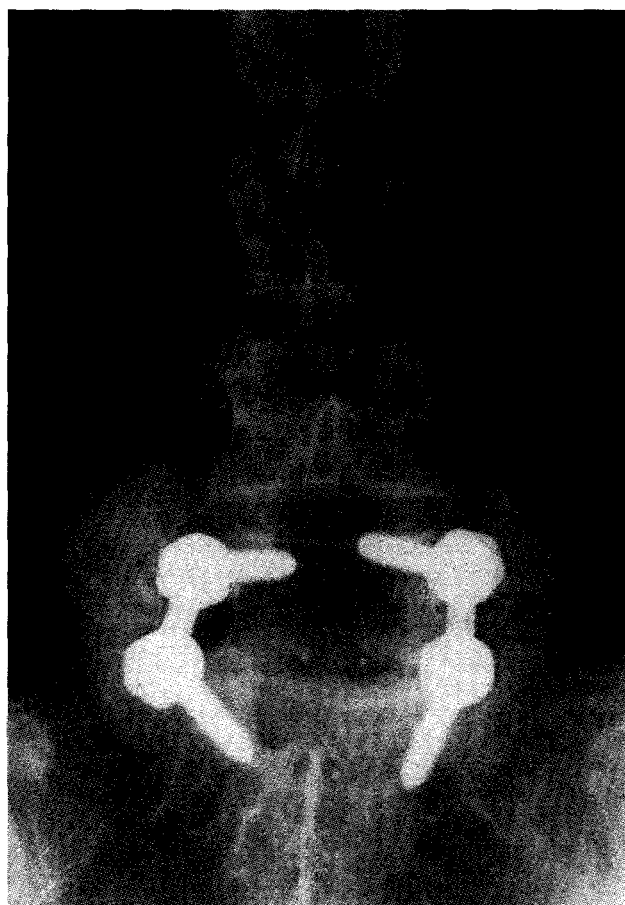


Figure 2. Case example (RB) showing 2-week postoperative radiograph.

### Discussion

With better understanding of the various biological factors that initiate, maintain, and regulate the complex process of osteogenesis, researchers are now looking towards manipulation of the biological environment of the site of bone formation for enhancing bone fusions.

A major concern in delivery of the growth factors to the site of bone healing has been their short half-lives in systemic circulation, as noted by Nimni<sup>13</sup> in his review of the various methods used for targeted delivery of growth factors to specific tissues. PDGF has a half-life of about 2 min if injected intravenously, and TGF- $\beta$  in its active form is also cleared from the blood stream within a few minutes. Noda et al.<sup>14</sup> have demonstrated that the action of TGF- $\beta$  is only a local one with no influence on bone formation at sites distant from its application. It has also been noted by Kasprek et al.<sup>9</sup> and other investigators that these multiple growth factors are present at the same time at the site of bone formation and have a synergistic effect on each other. This has led to the philosophy of providing higher concentrations of growth factors at the actual site of bone formation in order to mimic the natural process of osteogenesis as closely as possible.

While discussing the delivery systems for BMP, Marshall Urist has suggested that "the ideal delivery systems for BMP are endogenous in nature and autogenic in origin."<sup>18</sup> The use of autologous platelet concentrate to deliver the growth factors locally is thus the ideal vehicle to provide the biological environment of the growing bone cells with a physiological combination of all growth factors that are needed to initiate the healing

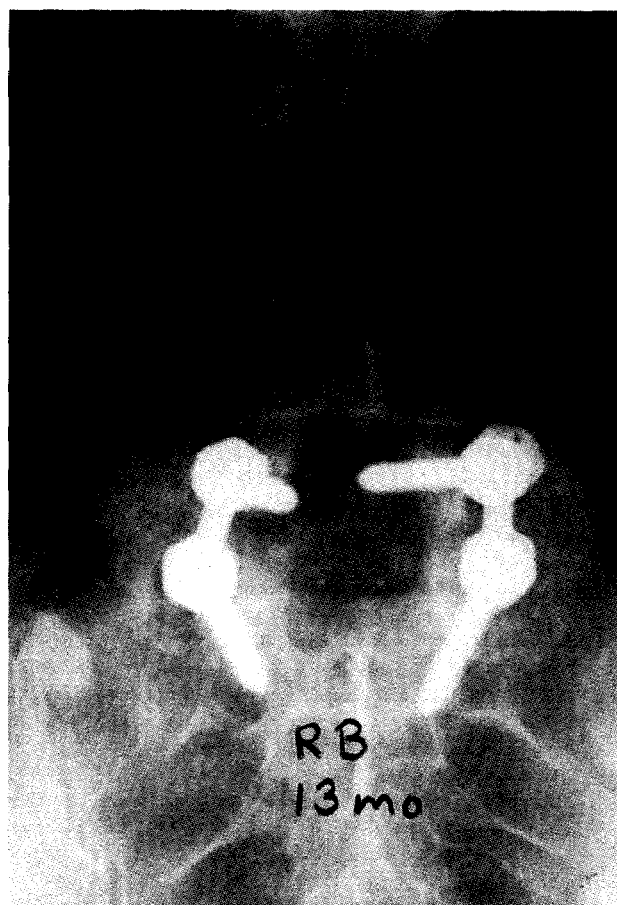


Figure 3. Case example (RB) at 13 months postoperatively showing radiographic evidence of solid fusion.

process and to create a positive feedback cycle that sustains itself through the healing process.

Marx et al.<sup>10</sup> have reported the use of platelet-rich plasma for enhancing graft incorporation in mandibular defect reconstruction. They have reported an average platelet count increase from 232,000 to 785,000 (a 338% increase). In our series, we have found that the average platelet count increased by about 306% in the platelet concentrate stage, and then up to 575% in the AGF concentrate state. Preliminary studies to evaluate the actual PDGF and TGF- $\beta$  levels were also carried out for a few samples; these showed that the PDGF levels increased from 30 to 60 ng/mL in the platelet concentrate, and then to 164 ng/mL in the AGF concentrate (546% increase). The TGF- $\beta$  levels increased from baseline of 52 to 122 ng/mL in Pcon and then to 198 ng/mL in the AGF concentrate (380% increase). Noda et al. have demonstrated a twofold increase in bone formation in rat calvariae by local injection of approximately 200 ng of TGF- $\beta$ . Smaller doses of 50 ng did not show similar results.<sup>14</sup> The AGF concentrate seems to achieve TGF levels of 198 ng/mL, which compare to the reported effective value of 200 ng/mL. Though there is no direct way of measuring the actual effect on bone in this study, the radiographic and clinical evidence seems to support the hypothesis that the AGF concentrate is effective in stimulating early bony union.

Another advantage of using the AGF-thrombin mixture is that it can also act as a binding medium for the autograft-HA mixture, making it easier to handle and place into the graft site. However, the most significant benefit of using the AGF concentrate is its being

autologous, endogenously derived, and easily available. There are no issues about immunogenicity or transmission of infection. There are no known local or systemic side effects or adverse effects. The process is also considerably cost effective as compared with use of purified or recombinant growth factors, and also it may be more physiologically sound to provide a combination of all factors in the platelets rather than individual factors.

#### Case Example

RB, a 53-year-old woman, presented with degenerative disc disease at L5-S1 and had laparoscopic intradiscal fusion. About 3 months postoperatively, she showed some settling and L5 root radiculopathy. She then had bilateral L5-S1 posterolateral fusion with a mixture of autograft and HA with AGF-thrombin. An L5 laminectomy and L5-S1 posterior stabilization with Moss Miami instrumentation was also done. The patient is now 15 months postsurgery and has a solid anterior and posterior fusion as seen on radiological and clinical examination (Figures 2 and 3).

#### Conclusion

Our early experience with AGF concentrate, prepared by ultra-concentration of platelets as a biological enhancer of fusion in lumbar fusions, suggests that local application of growth factors seems to promote early maturation of bony fusion and gives good fusion results even when used at levels higher than L5-S1. Further study of the actual concentrations of the growth factors in the AGF samples is being undertaken in order to validate these findings by laboratory evidence.

Given the osteoconductive properties of HA and the osteoconductive properties of AGF concentrate, it may be possible to avoid second-site autograft harvesting in future studies. In addition, potentially osteogenic cells from bone marrow extract or other sources of stem cells could be added to this combination to provide an "ideal" graft substitute.<sup>1</sup>

#### References

1. Baylink, D. J., et al. Growth factors to stimulate bone formation. *J Bone Miner Res* 2(Suppl.):565-572; 1993.
2. Canalis, E., et al. Effects of platelet-derived growth factor on bone formation in vitro. *J Cell Physiol* 140:530-537; 1989.
3. Canalis, E. Effect of growth factors on bone cell replication and differentiation. *Clin Orthop* 193:246-263; 1985.
4. Caplan, A. I. Mesenchymal stem cells. *J Orthop Res* 9:641-650; 1991.
5. Centrella, M., et al. Human platelet-derived transforming growth factor- $\beta$  stimulates parameters of bone growth in fetal rat calvariae. *Endocrinology* 119:2306-2312; 1986.
6. Centrella, M., et al. Platelet-derived growth factor enhances deoxyribonucleic acid and collagen synthesis in osteoblast-enriched cultures from fetal rat parietal bone. *Endocrinology* 125:13-19; 1989.
7. Gospodarowicz, D. Growth factors and their action in vivo and in vitro. *J Pathol* 141:201-233; 1983.
8. Howes, R., et al. Platelet derived growth factor enhances demineralized bone matrix induced cartilage and bone formation. *Calcif Tissue Int* 42:34-38; 1988.
9. Kasperk, C. H., et al. Interactions of growth factors present in bone matrix with bone cells effects on DNA synthesis and alkaline phosphatase. *Growth Factors* 3:147-158; 1990.
10. Marx, R. E., et al. Platelet-rich plasma: Growth factor enhancement for bone grafts. *Oral Surg Oral Med Oral Pathol Oral Radiol Endod* 85:638-646; 1998.
11. Mohan, S., et al. Bone growth factors. *Clin Orthop* 263:30-48; 1991.
12. Ng, K. W., et al. Stimulation of DNA synthesis by epidermal growth factor in osteoblast-like cells. *Calcif Tissue Int* 35:624-628; 1983.
13. Nimni, M. E. Polypeptide growth factors: targeted delivery systems. *Biomaterials* 18:1201-1225; 1997.
14. Noda, M., et al. In vivo stimulation of bone formation by transforming growth factor  $\beta$ . *Endocrinology* 124:2991-2994; 1998.
15. Pfeilschifter, J., et al. Stimulation of bone matrix apposition in vitro by local growth factors: a comparison between insulin-like growth factor I, platelet-derived growth factor, and transforming growth factor  $\beta$ . *Endocrinology* 127:69-75; 1990.
16. Seppa, H., et al. Platelet-derived growth factor in chemotactic for fibroblasts. *J Cell Biol* 92:584-588; 1982.
17. Slater, M., et al. Involvement of platelets in stimulating osteogenic activity. *J Orthop Res* 13:655-663; 1995.
18. Marshall, U. The search for and discovery of bone morphogenetic protein. *Bone Grafts, Derivatives & Substitutes*. 315-362.